

Virtual Sonography for Novice Sonographers: Usefulness of SYNAPSE VINCENT[®] with Pre-Check Imaging of Tumor Location

Chikara Ogawa^{a,b} Yasunori Minami^a Yumiko Morioka^b Akiyo Noda^b
Soichi Arasawa^b Masako Izuta^b Atsushi Kubo^b Toshihiro Matsunaka^b
Noriyuki Tamaki^b Mitsushige Shibatouge^b Masatoshi Kudo^a

^aDepartment of Gastroenterology and Hepatology, Kinki University School of Medicine, Osaka-Sayama, and

^bDepartment of Gastroenterology and Hepatology, Takamatsu Red Cross Hospital, Takamatsu, Japan

Key Words

SYNAPSE VINCENT[®] · Ultrasound beginners · Virtual sonography

Abstract

Purpose: To evaluate the usefulness of a virtual ultrasound (US) imaging device as a tool to assist novice sonographers.

Materials and Methods: A prospective blinded pilot study was conducted involving patients with liver lesions. Two sonographers and 2 medical doctors with less than 5 years of experience performed US examinations. The time needed to detect liver lesions on US and the success rate for detecting liver lesions with and without using the virtual US imaging device SYNAPSE VINCENT[®] (Fujifilm Medical Co., Tokyo, Japan) before US examination were evaluated. **Results:** Thirty-two patients with the following 42 liver lesions were included: liver cyst (n = 24), hemangioma (n = 8), hepatocellular carcinoma (n = 6), and liver metastasis (n = 4). The maximal diameter of these lesions ranged from 0.3 to 1.5 cm (mean ± SD, 0.8 ± 0.4). The average time for detecting liver lesions on US was 47.8 s (range, 7–113) with VINCENT and 112.9 s (range, 14–313) without VINCENT before US examination. There were significant differences in the duration of

US examination with and without VINCENT (p = 0.0002, Student's t test). The rates for accurately detecting liver lesions were 100 and 76.2% (16/21) in US beginners with and without VINCENT, respectively. Significantly higher detection rates were found in the US beginners who used VINCENT compared to those who did not use VINCENT (p = 0.047, Fisher's exact test). **Conclusion:** Before US examination, a reference with VINCENT could contribute to the successful detection of liver lesions and could be time-saving for US beginners.

© 2014 S. Karger AG, Basel

Introduction

Multidetector CT has been in clinical use since the late 1990s, and 3D imaging technology has markedly advanced. At the beginning of its clinical application, CT image reconstruction focused on displaying organs in real time [1, 2]. Recently, 3D imaging analysis has diversified. The ease and speed of obtaining needed images from 3D volume data have become important for the treatment of liver tumors, especially radiofrequency ablation for hepatocellular carcinoma [3, 4]. Especially in the liver, diag-

nostic imaging offers diverse modalities, including non-invasive evaluations [5–14]. Many types of imaging softwares using multiplanar reconstruction (MPR) have become available for the diagnosis and/or treatment guidance for liver cancers [15–18].

Ultrasound (US) fusion imaging (Real-Time Virtual Sonography, HITACHI ALOKA Medical Systems, Tokyo, Japan; Fusion, GE Healthcare, Chalfont St. Giles, UK; Smart Fusion, Toshiba Medical Systems, Tokyo, Japan) is a new system using MPR, and fusion imaging of B-mode US and CT/MRI can be displayed simultaneously and in real time according to the angle of the transducer in the magnetic field [19–22]. Fusion imaging can help us understand the 3D relationship between the liver vasculature and tumors. However, this system only operates with high-end US machines, and the fusion process is somewhat complex.

The volume analyzer SYNAPSE VINCENT® (Fujifilm Medical Co., Tokyo, Japan) is a 3D image analysis system that enables quick and easy access to high-definition 3D images of organs and vessels using previously captured CT or MRI, while also providing highly practical analysis functions at the workstation [23]. In particular, this can also generate virtual sonographic images using MPR with a quick and easy operation. In this study, we evaluated the usefulness of SYNAPSE VINCENT, a virtual US imaging device, as a tool to assist US beginners.

Materials and Methods

A prospective blinded pilot study was conducted involving patients with liver lesions. Two medical doctors and 2 sonographers with less than 5 years of experience performed US examinations. The primary objective was to compare the liver lesion detecting time on US and the success rate for detecting liver lesions with or without using the virtual US imaging device SYNAPSE VINCENT before US examination.

Equipment

The local area network system is connected to a computer with SYNAPSE (Fujifilm Medical Co.), a medical imaging and information management system, at the Takamatsu Red Cross Hospital. VINCENT is an application of imaging analyses using SYNAPSE and can display 2D MPR images as virtual sonography corresponding to the angle in the plane of 3D volume image data. This angle of the plane can be operated quickly and freely at the workstation for scanning in epigastric, subcostal, and intercostal positions.

B-mode sonographic scans were obtained using LOGIQ E9 (GE Healthcare) with a 2- to 5-MHz convex probe (C1–5D) and a 4- to 9-MHz linear probe (9LD), an Ascendas (HITACHI ALOKA Medical Systems) with a 1- to 5-MHz convex probe (EUP C715)

and a 3- to 7-MHz linear probe (EUP L52), or a Xario XG (Toshiba Medical Systems) with a 3- to 6-MHz convex probe (PVT-375BT).

CT was performed using a 64-slice multidetector-row CT scanner (Aquilion 64, Toshiba Medical Systems) with the following scan parameters: reconstructed slice thickness = 1 mm; rotation time = 0.5 s; helical pitch = 23.0; pitch factor = 0.791; X-ray tube parameters = 120 kV, 300–400 mA. Triple-phase contrast-enhanced CT was performed at 40, 70, and 180 s after initiating the injection of contrast media to obtain hepatic arterial, portal venous, and equilibrium phase images, respectively. A total of 100 ml of nonionic contrast material containing 300 mg of iodine per milliliter (Iopamidol, Bayer Yakuhin, Osaka, Japan) was injected intravenously at a rate of 3 ml/s using an automatic power injector.

Evaluation

Patients with liver tumors who have previously been diagnosed by dynamic CT or MRI were selected for this study. US beginners were permitted to obtain imaging information of some patients using VINCENT, whereas information on previous imaging results of other patients was withheld.

The liver was examined first using a subcostal approach in sagittal and paraxial planes. As a rule, the right hepatic lobe was also examined with a lateral approach through the intercostal space. Sonographic reports and images were reviewed in conjunction with CT/MRI to determine whether a determinate lesion shown on CT/MRI could be detected sonographically and to confirm lesion correspondence. Thereby, the detection rates and duration of detecting liver lesions on US were evaluated.

Statistical Analysis

All values are expressed as the mean \pm standard deviation (SD). Comparisons between the two groups were analyzed using Student's t test and Fisher's exact test. $p < 0.05$ was considered significant. Statistical analyses were performed using Microsoft Excel 2013 for Windows.

Results

This pilot study involved 32 patients undergoing routine US examinations. All patients with the following 42 liver lesions were included: liver cyst ($n = 24$), hemangioma ($n = 8$), hepatocellular carcinoma ($n = 6$), and liver metastasis ($n = 4$). The maximal diameter of these lesions ranged from 0.3 to 1.5 cm (mean \pm SD, 0.8 ± 0.4) on CT.

The average time for detecting liver lesions on US was 47.8 s (range, 7–113) with VINCENT and 112.9 s (range, 14–313) without VINCENT before US examination. There were significant differences in the duration of US examination with and without VINCENT ($p = 0.0002$, Student's t test; fig. 1).

The rates for accurately detecting liver lesions were 100% (21/21) and 76.2% (16/21) in US beginners with

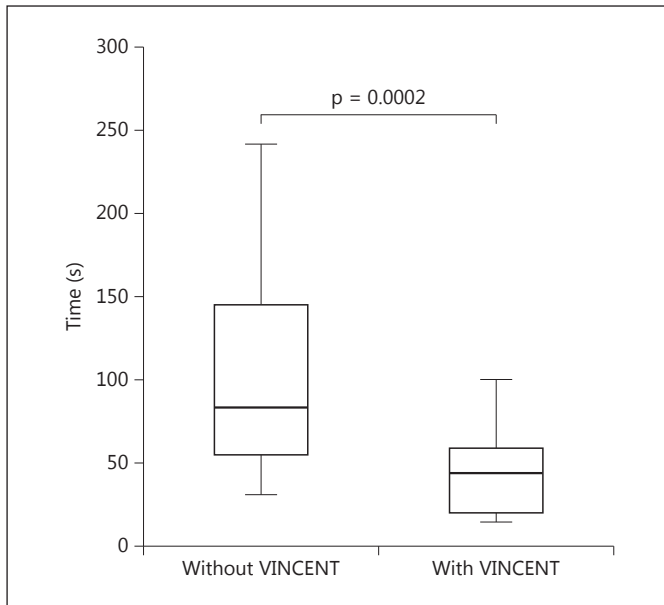


Fig. 1. The time needed to detect the liver lesions with and without VINCENT.

and without VINCENT, respectively. Significantly higher detection rates were found in the US beginners who used VINCENT compared to those who did not use VINCENT ($p = 0.047$, Fisher's exact test).

Discussion

Preparation is a necessary ingredient for success, and even more so for beginners. This study demonstrated that pre-check imaging by SYNAPSE VINCENT could contribute to the successful detection of liver lesions and could be time-saving on US examination for beginners. In general, axial imaging on CT is common in clinical use, whereas US shows cross-sectional images with various angles. In particular, an intercostal view of the liver on US provides quite a different image from usual CT images because the intercostal view is in a diagonal direction against the body trunk. Therefore, it is often difficult for US beginners to understand the 3D anatomy of the liver and display available images with an intercostal view. Moreover, US images may differ from a familiar view because the shape of the liver changes after surgical liver resection. This could also lead to wasting time on US examination. However, SYNAPSE VINCENT has the potential to resolve these problems. VINCENT can

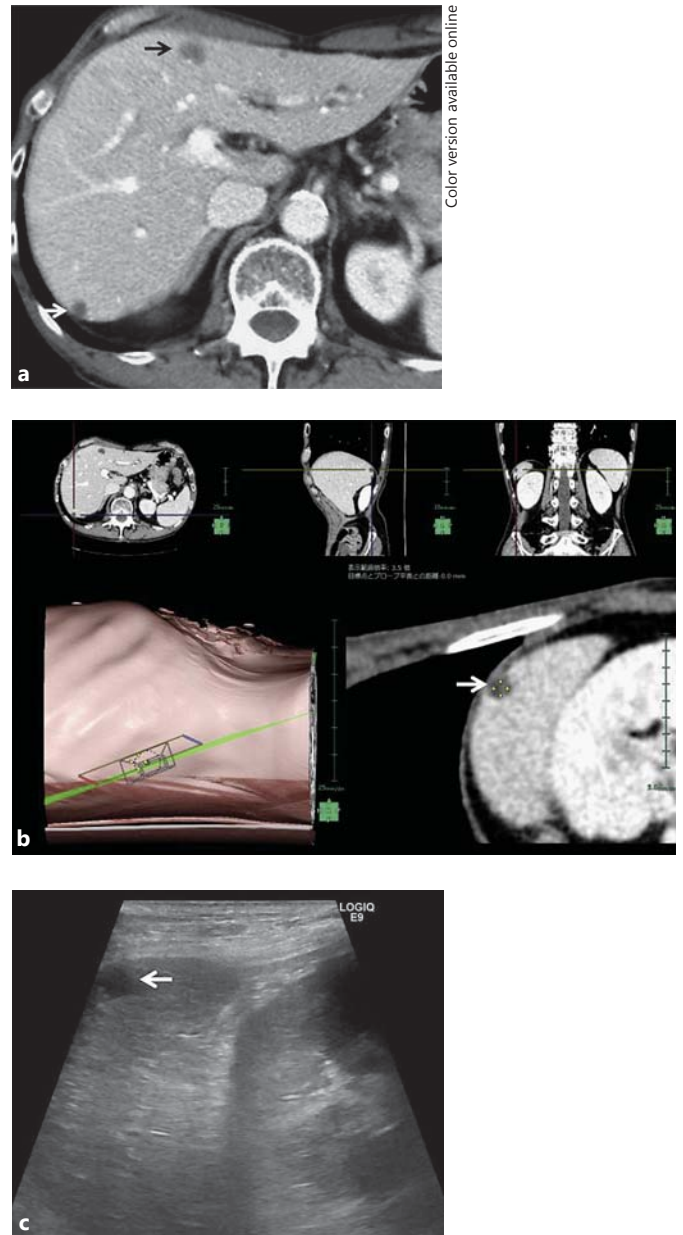


Fig. 2. Imaging of a 66-year-old man with liver cysts. **a** Transverse portal phase CT shows two cysts (arrows) in segment III and VI of the liver. **b** Screen shot shows setting windows for VINCENT. Upper images show the transverse, sagittal, and coronal views for the cyst in segment VI. The lower left image shows that the transducer angle in the plane of the body trunk indicates images obtained from the subcostal view. The lower right image displays the virtual US image and the cyst as low-density area. **c** B-mode US image corresponds to the virtual US image. The cyst is shown as low echoic area (arrow). Our US beginners missed this cyst without using VINCENT because the rib bone hid it.

simulate US examinations by virtual US imaging at a workstation [23]. Preparation using VINCENT could promote an efficient and successful US examination (fig. 2).

While the basic technical development depends on the frequency of US examination, successful experience would stimulate a US beginner's growth. This study gives powerful support for the effectiveness of training in early-phase US skill acquisition with the use of VINCENT. To perform US examination with competence, not only the sonographer, but also the medical doctor must have a good understanding of the abdominal anatomy. The use of various models and stimulators will help to understand the abdominal anatomy and shorten the learning curve. Therefore, a training program with the use of virtual US imaging would shorten the learning curve for US beginners.

However, virtual US devices such as VINCENT should provide reference images at a workstation. Virtual US images do not completely correspond to US images. This imaging incompatibility could be attributed to

variations in the depth of breath holding on CT and US examination [20]. In addition, the liver is also rotated to varying degrees from the time when CT was previously captured.

The principal limitation of this study is that it could suffer from selection bias because patients with liver lesions were enrolled according to the senior doctors' subjective selections. Second, it is a preliminary study with a relatively small number of patients. Further studies of this technique with a larger number of patients are warranted.

In summary, SYNAPSE VINCENT could display virtual US images clearly and smoothly. Before US examination, a reference with VINCENT could contribute to the successful detection of liver lesions and could be time-saving for US beginners.

Disclosure Statement

The authors declare that no financial or other conflicts of interest exist in relation to the content of this article.

References

- 1 Lee KS, Yoon JH, Kim TK, Kim JS, Chung MP, Kwon OJ: Evaluation of tracheobronchial disease with helical CT with multiplanar and three-dimensional reconstruction: correlation with bronchoscopy. *Radiographics* 1997;17:555–567; discussion 568–570.
- 2 Lawler LP, Fishman EK: Multi-detector row CT of thoracic disease with emphasis on 3D volume rendering and CT angiography. *Radiographics* 2001;21:1257–1273.
- 3 Fishman EK, Ney DR, Heath DG, Corl FM, Horton KM, Johnson PT: Volume rendering versus maximum intensity projection in CT angiography: what works best, when, and why. *Radiographics* 2006;26:905–922.
- 4 Lin SM: Local ablation for hepatocellular carcinoma in Taiwan. *Liver Cancer* 2013;2:73–83.
- 5 Lee JM, Yoon JH, Joo I, Woo HS: Recent advances in CT and MR imaging for evaluation of hepatocellular carcinoma. *Liver Cancer* 2012;1:22–40.
- 6 Ricke J, Seidensticker M, Mohnike K: Noninvasive diagnosis of hepatocellular carcinoma in cirrhotic liver: current guidelines and future prospects for radiological imaging. *Liver Cancer* 2012;1:51–58.
- 7 Donati OF, Fischer MA, Chuck N, Hunziker R, Weishaupt D, Reiner CS: Accuracy and confidence of Gd-EOB-DTPA enhanced MRI and diffusion-weighted imaging alone and in combination for the diagnosis of liver metastases. *Eur J Radiol* 2013;82:822–828.
- 8 Forner A, Vilana R, Ayuso C, Bianchi L, Sole M, Ayuso JR, Boix L, Sala M, Varela M, Llovet JM, Bru C, Bruix J: Diagnosis of hepatic nodules 20 mm or smaller in cirrhosis: prospective validation of the noninvasive diagnostic criteria for hepatocellular carcinoma. *Hepatology* 2008;47:97–104.
- 9 Kudo M, Hatanaka K, Kumada T, Toyoda H, Tada T: Double-contrast ultrasound: a novel surveillance tool for hepatocellular carcinoma. *Am J Gastroenterol* 2011;106:368–370.
- 10 Bota S, Piscaglia F, Marinelli S, Pecorelli A, Terzi E, Bolondi L: Comparison of international guidelines for noninvasive diagnosis of hepatocellular carcinoma. *Liver Cancer* 2012;1:190–200.
- 11 Inoue T, Kudo M, Komuta M, Hayaishi S, Ueda T, Takita M, Kitai S, Hatanaka K, Yada N, Hagiwara S, Chung H, Sakurai T, Ueshima K, Sakamoto M, Maenishi O, Hyodo T, Okada M, Kumano S, Murakami T: Assessment of Gd-EOB-DTPA-enhanced MRI for HCC and dysplastic nodules and comparison of detection sensitivity versus MDCT. *J Gastroenterol* 2012;47:1036–1047.
- 12 Alzaraa A, Gravante G, Chung WY, Al-Leswas D, Morgan B, Dennison A, Lloyd D: Contrast-enhanced ultrasound in the preoperative, intraoperative and postoperative assessment of liver lesions. *Hepatol Res* 2013;43:809–819.
- 13 Joo I, Choi BI: New paradigm for management of hepatocellular carcinoma by imaging. *Liver Cancer* 2012;1:94–109.
- 14 Salvatore V, Bolondi L: Clinical impact of ultrasound-related techniques on the diagnosis of focal liver lesions. *Liver Cancer* 2012;1:238–246.
- 15 Lee SW, Shinohara H, Matsuki M, Okuda J, Nomura E, Mabuchi H, Nishiguchi K, Takatori K, Narabayashi I, Tanigawa N: Preoperative simulation of vascular anatomy by three-dimensional computed tomography imaging in laparoscopic gastric cancer surgery. *J Am Coll Surg* 2003;197:927–936.
- 16 Taketomi A, Takeishi K, Mano Y, Toshima T, Motomura T, Aishima S, Uchiyama H, Yoshizumi T, Shirabe K, Maehara Y: Total resection of the right hepatic vein drainage area with the aid of three-dimensional computed tomography. *Surg Today* 2012;42:46–51.

- 17 Minami Y, Kudo M, Chung H, Inoue T, Takahashi S, Hatanaka K, Ueda T, Hagiwara H, Kitai S, Ueshima K, Fukunaga T, Shiozaki H: Percutaneous radiofrequency ablation of sonographically unidentifiable liver tumors. Feasibility and usefulness of a novel guiding technique with an integrated system of computed tomography and sonographic images. *Oncology* 2007;72(suppl 1):111–116.
- 18 Fukuda H, Ito R, Ohto M, Sakamoto A, Otsuka M, Togawa A, Miyazaki M, Yamagata H: US-CT 3D dual imaging by mutual display of the same sections for depicting minor changes in hepatocellular carcinoma. *Eur J Radiol* 2012;81:2014–2019.
- 19 Hirooka M, Iuchi H, Kumagi T, Shigematsu S, Hiraoka A, Uehara T, Kurose K, Horiike N, Onji M: Virtual sonographic radiofrequency ablation of hepatocellular carcinoma visualized on CT but not on conventional sonography. *AJR Am J Roentgenol* 2006;186:S255–S260.
- 20 Minami Y, Chung H, Kudo M, Kitai S, Takahashi S, Inoue T, Ueshima K, Shiozaki H: Radiofrequency ablation of hepatocellular carcinoma: value of virtual CT sonography with magnetic navigation. *AJR Am J Roentgenol* 2008;190:W335–W341.
- 21 Okamoto E, Sato S, Sanchez-Siles AA, Ishine J, Miyake T, Amano Y, Kinoshita Y: Evaluation of virtual CT sonography for enhanced detection of small hepatic nodules: a prospective pilot study. *AJR Am J Roentgenol* 2010;194:1272–1278.
- 22 Minami Y, Kitai S, Kudo M: Treatment response assessment of radiofrequency ablation for hepatocellular carcinoma: usefulness of virtual CT sonography with magnetic navigation. *Eur J Radiol* 2012;81:e277–e280.
- 23 Ohshima S: Volume analyzer SYNAPSE VINCENT for liver analysis. *J Hepatobiliary Pancreat Sci* 2014;21:235–238.